

herniorrhaphy for the treatment of femoral hernias [J] Surgery, 2010, 148(5):976-991

- [11] [J]. , 2012, 16(21):3873-3876
- [12] [J]. : , 2014, 8(3):207-209

(本文编辑 姜晖)

本文引用格式:

[J]. , 2015, 24(8):1205-1208 doi:10.3978/j.issn.1005-6947.2015.08.031

Cite this article as: OUYANG Y. Risk factors of complications of Ultra hernia system (UHS) double patch repair for incarcerated inguinal hernia[J]. Chin J Gen Surg, 2015, 24(8):1205-1208. doi:10.3978/j.issn.1005-6947.2015.08.031



doi:10.3978/j.issn.1005-6947.2015.08.032
http://dx.doi.org/10.3978/j.issn.1005-6947.2015.08.032
Chinese Journal of General Surgery, 2015, 24(8):1208-1209.

· 病案报告 ·

肝包虫并发支气管胆瘘 1 例

赵春选

(甘南藏族自治州人民医院 普通外科, 甘肃 合作 747000)

关键词

中图分类号: R657.4

患者 28 岁, CT 示右肺下叶实变, 8 cm× 5.5 cm
 10 d 后复查 CT 示右肺下叶实变, 13 cm× 10 cm
 11.1× 10⁹/L, 0.68
 37℃, 102 /min, 12.3 μmol/L
 110/80 mmHg, 1 mmHg=0.133 kPa, 48 U/L, 29 U/L
 22 /min, 5 mL
 Alice

7 cm
 3 cm
 X
 1
 2

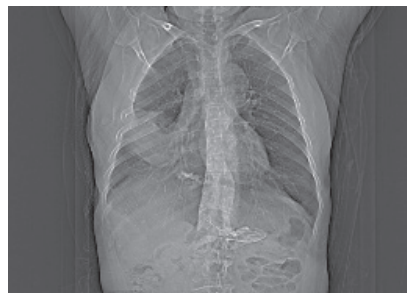

图 1 右侧胸腔积液

收稿日期: 2015-01-04

修订日期: 2015-06-03

作者简介:

通信作者: Email: gsgnzct@126.com

14 cm

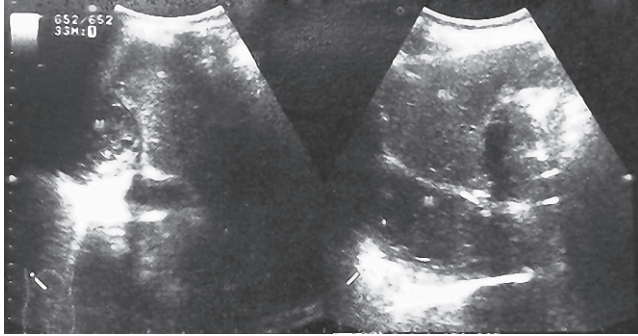

Figure 1

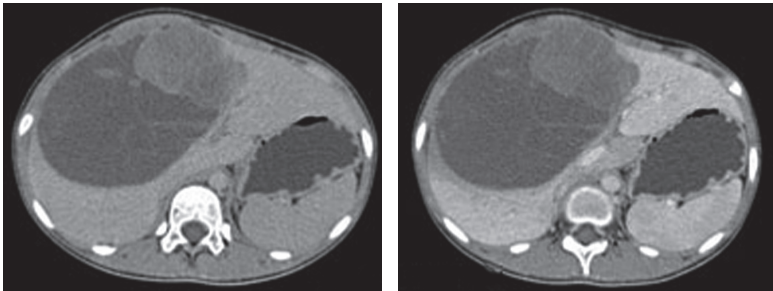


Figure 2

[1] J. H. [2] B. H. [3] D. H. [4] B. H. [5] [6] [7] [8] [9] [10] [11] [12] [13] [14] [15] [16] [17] [18] [19] [20] [21] [22] [23] [24] [25] [26] [27] [28] [29] [30] [31] [32] [33] [34] [35] [36] [37] [38] [39] [40] [41] [42] [43] [44] [45] [46] [47] [48] [49] [50] [51] [52] [53] [54] [55] [56] [57] [58] [59] [60] [61] [62] [63] [64] [65] [66] [67] [68] [69] [70] [71] [72] [73] [74] [75] [76] [77] [78] [79] [80] [81] [82] [83] [84] [85] [86] [87] [88] [89] [90] [91] [92] [93] [94] [95] [96] [97] [98] [99] [100]

UBDU